

CASE REPORT

ENDODONTIC MANAGEMENT OF FUSED MAXILLARY LATERAL INCISOR: A CASE REPORT

M. B. Wavdhane¹, Pradnya Bansode², Seema Pathak³, Kapil Wahane⁴, Shirish Khedgikar⁵

HOW TO CITE THIS ARTICLE:

M. B. Wavdhane, Pradnya Bansode, Seema Pathak, Kapil Wahane, Shirish Khedgikar. "Endodontic Management of Fused Maxillary Lateral Incisor: A Case Report". *Journal of Evolution of Medical and Dental Sciences* 2014; Vol. 3, Issue 65, November 27; Page: 13640-13642, DOI: 10.14260/jemds/2014/3909

ABSTRACT: Fusion is a rare occurrence and its definitive diagnosis is of prime importance for successful root canal treatment. This case report discusses the endodontic and esthetic management of fused maxillary right lateral incisor. Root canal treatment was performed on the fused tooth. Nickel Chromium with ceramic crown was fabricated in the shape of lateral incisor. The patient remained asymptomatic and there was a reduction in the size of periapical radiolucency after six months.

KEYWORDS: Fusion, root canal therapy, esthetic restoration.

INTRODUCTION: Dental anomalies are seen in either the primary or permanent dentition.¹⁻⁴ Maxillary lateral incisor teeth may vary dramatically in their internal and external morphology.⁵ Fusion and germination are developmental anomalies of dental hard tissues. Fusion occurs because of the union of two separated tooth germs with a resultant formation of joint tooth with confluence of dentine.⁶⁻⁷

Fusion predominantly occurs in incisors and canines with apparent equal distribution between the two jaws and their incidence is very rare in molars.⁸

However, the exact etiology of fusion is unknown. A pressure or physical force producing close contact between two developing tooth buds has been reported as one possible cause. Genetic predisposition and racial predilection have also been reported as contributing factors in the literature.⁹

The management of a fused tooth with pulpal involvement may be considered as an endodontic dilemma. This case reports the management of discolored and mesiodistally wide fused maxillary lateral incisor.

CASE REPORT: A 30yr old male patient reported to the Department of Conservative Dentistry and Endodontics, Government Dental College and Hospital Aurangabad, with chief complaint of large discolored front tooth.

Intraoral examination revealed the presence of an abnormally large, discolored right maxillary permanent lateral incisor. Intraoral periapical radiographic evaluation revealed the two canals and periapical radiolucency associated with fused tooth. The mesiodistal width of fused tooth was wide. The occurrence of fusion was only unilateral. Findings were confirmed by CBCT.

Pulp vitality tests were performed. Thermal test and electrical pulp tester elicited a negative response when compared to control teeth. Based on the diagnosis, root canal therapy followed by functional and esthetic restoration was planned.

Under rubber dam isolation, coronal access to the two root canals was established. Cleaning and shaping was achieved using stainless steel K- files (Mani, Japan) by Crown down technique. Final apical file used was 60 size (ISO 0.02 taper) for the main canal and 30 size (ISO 0.02 taper) for the

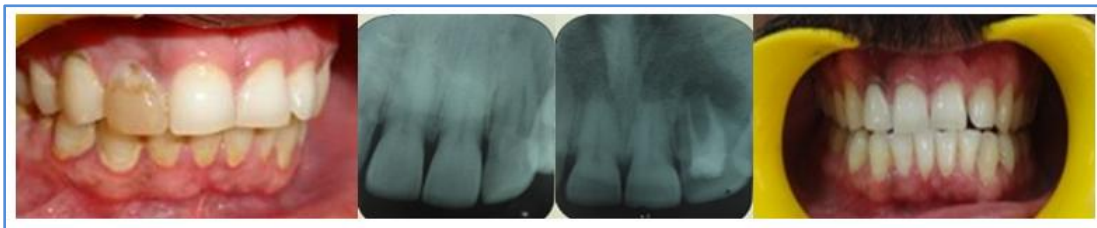
CASE REPORT

other canal. Irrigant was used 3% sodium hypochloride. The canals were finally flushed with normal saline and then dried with absorbent paper points. Calcium hydroxide paste (RC Cal, Prime Dental products, Mumbai, India.) was kept for one week.

The patient returned after one week. The patient was asymptomatic and obturation was planned. Obturation was done using AH-26 sealer () with gutta percha (Dentsply Maillefer, Ballaigues) by lateral compaction technique. The coronal access was sealed, with glass ionomer cement. (GC Fuji II, GC. Corp, Tokyo, Japan).

Nickel chromium (CB 80 Nonprecious alloy Dentsply-Sankin) with ceramic facing was fabricated in the shape of lateral incisor. The crown was luted with type I glass ionomer cement (GC Fuji I, GC. Corp, Tokyo, Japan).

The patient was reexamined after 6 months for review. The tooth was asymptomatic and radiograph shows healing and repair at periapical area.



DISCUSSION: The morphology of fusion has to be differentiated from similar developmental anomalies of the tooth like gemination for successful endodontic and esthetic management. In the present case, two definite and separate root canals were present. The fused teeth generally show differences in two halves of the joined crown. Both the clinical and radiographic findings were suggestive of fusion. De Deus (1992) reported that 3% of maxillary incisors might have two canals.¹⁰

Dental anomalies occur during the embryological and developmental life of the tooth and usually involve a single tooth germ. Some consider gemination as division of single tooth germ by invagination and subsequent development of two teeth, whereas fusion occurs when two separated tooth germs unite. The degree of union will depend on the stage of tooth development that has occurred at the time of fusion, with the union of dentin being the main criterion.⁴

In the present case endodontic treatment was opted because tooth was discoloured, nonvital with associated periapical lesion. The final restoration using Nickel Titanium crown with ceramic facing was done to enhance esthetic and function.

The patient was instructed to follow strict oral hygiene measure and directed to report for periodic evaluation.

CONCLUSION: An esthetically compromised tooth with unusual root canal morphology because of fusion was managed by endodontic treatment followed by full crown to restore the biomechanical, structural and esthetic integrity. Such situations of developmental abnormalities demand interdisciplinary approach for successful management.

REFERENCES:

1. Sawayer M, Peikkoff MD, Trott JR, Endodontic therapy in an usual case of fusion. J Endodon 1980; 6: 796-8.

CASE REPORT

2. Gregory WA. A case of extreme microdontia. Oral surg Oral Med Oral Pathol 1990; 69: 658.
3. Chen RJ, Yang JF, Chao TC. Invaginated tooth associated with periodontal abscess. Oral surg Oral Med Oral Pathol 1990; 69: 659.
4. Yanioglu F, Kartal N. Endodontic treatment of fused maxillary lateral incisor. J Endod 1998; 24: 57-59.
5. Smith BE, Carroll B. Maxillary lateral incisor with two developmental grooves. Oral surg Oral Med Oral Pathol 1990; 70: 523-25.
6. Shafer WG, Hine NK, Levy BM: Developmental disturbances of oral and paraoral structures. In: A text book of oral pathology, 4th edition. Philadelphia, PA: WB Saunders, 1993: 38-9.
7. Neville BW, Damm DD, Allen CM, Bouquet JE. Abnormalities of teeth. In: Oral and maxillofacial pathology, 2nd ed. WB Saunders company, imprint of Elsevier science, Linacre house, Jordan hills, Oxford, UK 2002: 74.
8. Tsesis I, Steinbock N, Rosenberg E, Kaufman AY. Endodontic treatment of developmental anomalies in posterior teeth: treatment of geminated/ fused teeth-report of two cases. Int. Endod J, 2003; 36: 372-9.
9. Nunes E, de Moraes IG, Novaes PMO, de Sousa SMG. Bilateral fusion of mandibular second molars with supernumerary teeth: Case report. Braz Dent J 2002; 13: 137-41.
10. Pereira AJA, Fidel RAS, Fidel SR. maxillary incisors with two canals; fusion, gemination or dens invaginatus? Braz Dent J 2000; 11: 141-6.

AUTHORS:

1. M. B. Wavdhane
2. Pradnya Bansode
3. Seema Pathak
4. Kapil Wahane
5. Shirish Khedgikar

PARTICULARS OF CONTRIBUTORS:

1. Assistant Professor, Department of Conservative Dentistry, GDC & H, Aurangabad.
2. Professor, Department of Conservative Dentistry, GDC & H, Aurangabad.
3. Associate Professor, Department of Conservative Dentistry, GDC & H, Aurangabad.

4. Assistant Professor, Department of Conservative Dentistry, GDC & H, Aurangabad.
5. Assistant Professor, Department of Conservative Dentistry, GDC & H, Aurangabad.

NAME ADDRESS EMAIL ID OF THE CORRESPONDING AUTHOR:

Dr. M. B. Wavdhane,
203, Department of Conservative Dentistry,
Government Dental College and Hospital,
Aurangabad.
Email: mbwadhavane@gmail.com

Date of Submission: 11/11/2014.
Date of Peer Review: 12/11/2014.
Date of Acceptance: 21/11/2014.
Date of Publishing: 27/11/2014.